

The District General Hospital
Endoscopy Unit – Ext 3677

Name: **Stephen RAINEY**
NHS no: **456 789 1234**
Date of birth: **21/11/1958**
Case note no: **X123456**

Address: Unisoft Medical Systems
First Floor
7 London Road
Enfield
Middlesex EN2 6BN

GP: Dr K K Singh
The Clinic
The Town
Enfield EN3 5XX

Status: Daycase/NHS
Hospital: The General Hospital
Ward: B7
Referring Cons: Dr Merrick
(General Medicine)

Flexible Cystoscopy Report 24th June 2006

History and indications

Dysuria, 2x nocturia and stress incontinence.
Smoking: stopped 5 years ago but smoked 30/day for 18 years
(27 pack/years).
Urine dipstick: Ketones 8 mmol/L
Leucocytes ++
Allergies: none

Examination

Abnormal abdominal examination: bladder mass
Digital rectal examination: normal enlarged prostate

Findings/Diagnoses

- Ureteric orifices normal and present
- Bladder, base (b): cystitis cystica
- Prostatic urethra (a): tumour
- Rest of urethra normal.

Follow up

Further investigations: mid-stream urine, urine cytology,
C-reactive protein and CT urogram.
Another flexible cystoscopy in 4 weeks and out-patient
appointment in 6 weeks.

List consultant/Supervising doctor

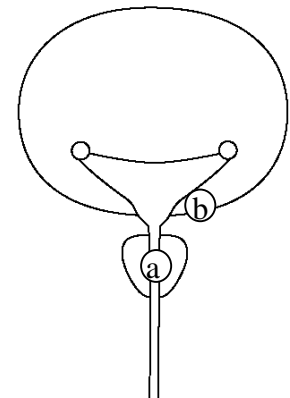
Dr J J Ensleigh/Dr Eric Haley
Cystoscopist 1: Dr Mamood Mehta

Instrument

CY240L - 1000034

Antibiotics

Gentamicin (IV) 80mg

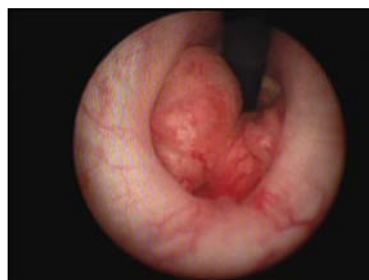
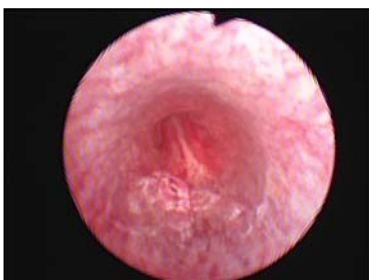
a: Prostatic urethra
(photographed)
b: Base

Specimens taken

Biopsy (x2 site a)

Dr Mamood Mehta, MBBS MRCS



Hospital no
X123456
NHS No
456 789 1234

HISTOLOGY

The District General Hospital

Date collected
24th May 2006

Surname
Rainey Sex
M
Forename
Stephen
Address
**Unisoft Medical Systems
First Floor
7 London Road
Enfield, Middlesex EN2 2BN**
DoB (age) **29th December 1932 (73 years)**

Previous biopsy numbers

For Lab Use

Date Rec'd

Date Reported

Investigations Required

Container ID	Specimens
<input type="text"/>	2 prostatic urethral biopsies from (a)

Clinical findings

History and Indications

Smoking: stopped 5 years ago but smoked 30/day for 18 years (27 pack/years).

Urine dipstick: Ketones 8 mmol/L

Leucocytes ++

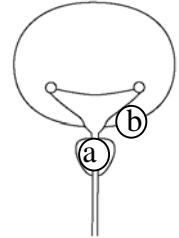
Findings/Diagnoses

Ureteric orifices normal and present

Bladder, base (b): cystitis cystica

Prostatic urethra (a): tumour

Rest of urethra normal



a: prostatic urethra
b: base

COPY TO

Signature